

Brief Opinion

The Novel Use of a Commercially Available Video-Conference Platform to Facilitate Multidisciplinary Target Volume Review and Delineation for Skull-Base Radiation Therapy During the Coronavirus Disease 2019 Pandemic



Amit Roy, MD,^{a,*} Neal Andruska, MD, PhD,^a Hilary L.P. Orlowski, MD,^b Patrik Pipkorn, MD, MSCI,^c and Mackenzie D. Daly, MD^a

Departments of ^aRadiation Oncology, ^bRadiology, and ^cOtolaryngology, Washington University School of Medicine, St Louis, Missouri

Received 21 June 2020; revised 5 September 2020; accepted 13 October 2020

Abstract

Multidisciplinary involvement in radiation therapy (RT) treatment planning is currently underused. A radiation oncologist sought input for generating target contours from a neuro-radiologist (NR) and otolaryngologist (OL) for 3 patients requiring skull-base RT during the coronavirus disease 2019 pandemic. A Health Insurance Portability and Accountability Act compliant virtual meeting between the radiation oncologist, NR, and OL was arranged. Involvement of the OL and NR led to significant changes in the clinical target volume for all patients. Our experience highlights the feasibility of using commercially available video-conference platforms for multidisciplinary target volume delineation for complex RT cases. Further applications include interdisciplinary contour review for RT cases requiring special expertise and joint attending/resident physician contour review for resident education. The video-conference platform technology has demonstrated benefit during the coronavirus disease 2019 pandemic, and we believe it will remain an integral component of our field moving forward.

© 2020 The Authors. Published by Elsevier Inc. on behalf of American Society for Radiation Oncology. This is an open access article under the CC BY-NC-ND license (<http://creativecommons.org/licenses/by-nc-nd/4.0/>).

Introduction

Accurate target delineation during radiation therapy (RT) treatment planning is required for optimal oncologic and toxicity outcomes.¹ Despite the presence of

contouring atlases and guidelines, considerable variation in contouring practices exists.² Efforts are underway to improve anatomy and radiology education among trainees.³ Interdisciplinary peer review often leads to contouring changes⁴ and the American Society for Radiation Oncology recently established the Peer-to-Peer Match program to assist radiation oncologists (ROs) currently in practice.⁵ Multidisciplinary input can also improve contours,⁶ and several clinical scenarios exist that may benefit from such collaboration. However, multidisciplinary involvement in RT treatment planning

Sources of support: This research did not receive any specific grant from funding agencies in the public, commercial, or not-for-profit sectors.

Disclosures: The authors have no relevant conflicts of interest to disclose.

* Corresponding author: Amit Roy, MD; E-mail: aroy@wustl.edu

<https://doi.org/10.1016/j.adro.2020.10.011>

2452-1094/© 2020 The Authors. Published by Elsevier Inc. on behalf of American Society for Radiation Oncology. This is an open access article under the CC BY-NC-ND license (<http://creativecommons.org/licenses/by-nc-nd/4.0/>).

has been underused due to multiple factors including lack of dedicated time, physical distance, and limited infrastructure.

In light of the coronavirus disease 2019 (COVID-19) pandemic, remote meetings through video-conference platforms (VCPs) have been widely implemented.^{7,8} Here, we present a case series demonstrating the novel use of a remote VCP for multidisciplinary review and modification of target volumes for skull-base RT.

Methods and Materials

This study was exempt from the institutional review board. An RO at our institution sought input for generating target volume contours from a neuro-radiologist (NR) and otolaryngologist (OL) for 3 patients requiring skull-base RT during the COVID-19 pandemic. All patients underwent computed tomography simulation, and additional diagnostic imaging (ie, preoperative computed tomography) was fused to the primary data set. The RO independently contoured a clinical target volume (CTV), denoted as CTV_RO, for each case. Contouring was performed using the Eclipse treatment planning system (TPS) (Varian Medical Systems Inc, Palo Alto, CA). A commercially available, Health Insurance Portability and Accountability Act (HIPPA)-compliant VCP (Zoom; Zoom Video Communications Inc, San Jose, CA) was used to arrange a remote meeting. The goal of this meeting was to review and generate multidisciplinary consensus target contours for each case.

Results

The RO began the meeting on her desktop workstation using the VCP. The NR and OL joined the session. The RO opened the TPS on her workstation and entered the contouring workspace for each patient. The RO shared her screen and gave screen controls to the NR using functionality of the VCP. This allowed the NR and OL to review, generate, and modify contours in the TPS. The session lasted 45 minutes.

Case 1

The patient was a 30-year-old woman who presented with progressive, symptomatic Gorham Stout disease involving the skull base.⁹ Given the rarity of this disease process, the RO wanted to ensure that the CTV included all areas with radiographic evidence of Gorham Stout disease. During the session, the NR contoured a CTV, denoted CTV_NR, with input from the OL. The RO had previously independently contoured the CTV_RO. The team reviewed the CTV_NR and CTV_RO (Fig 1). Similarities and differences in the 2 contours were reviewed. The CTV_NR included a greater extent of the maxilla, clivus, and temporal bone. The CTV_RO included a greater extent of the sphenoid and ethmoid sinuses. The RO then generated a final CTV by boolean of CTV_RO and CTV_NR.

Case 2

The patient was a 75-year-old man with pathologic T3NXMO squamous cell carcinoma of the right eyelid with multiple high-risk features, including positive surgical margin and perineural invasion requiring adjuvant RT. Given the location of the tumor and perineural invasion, the RO wanted to ensure optimal coverage of the inferior orbital nerve. The CTV_RO was copied into a new structure denoted as CTV_NR. The NR then adjusted the CTV_NR to include the right foramen rotundum and Meckel's cave (Fig 2).

Case 3

The patient was a 71-year-old man with pathologic T3NOM0 adenocystoid carcinoma of the right lacrimal gland status-post resection with positive surgical margins and perineural invasion requiring adjuvant RT. The RO wanted to ensure optimal coverage of at-risk skull-base structures. The CTV_RO was copied into a new structure, denoted as CTV_NR. The NR then modified the CTV_NR to include the foramen lacerum (Fig 3) given the potential route of spread.

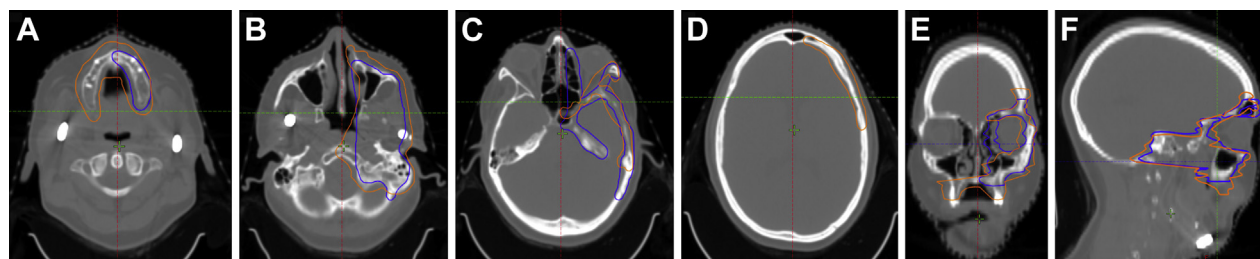


Figure 1 Clinical target volume (CTV) delineated by a radiation oncologist (RO) (blue) and a neuro-radiologist (NR)/otolaryngologist (OL) (orange) on axial (A-D), coronal (E), and sagittal (F) computed tomography (CT) images.

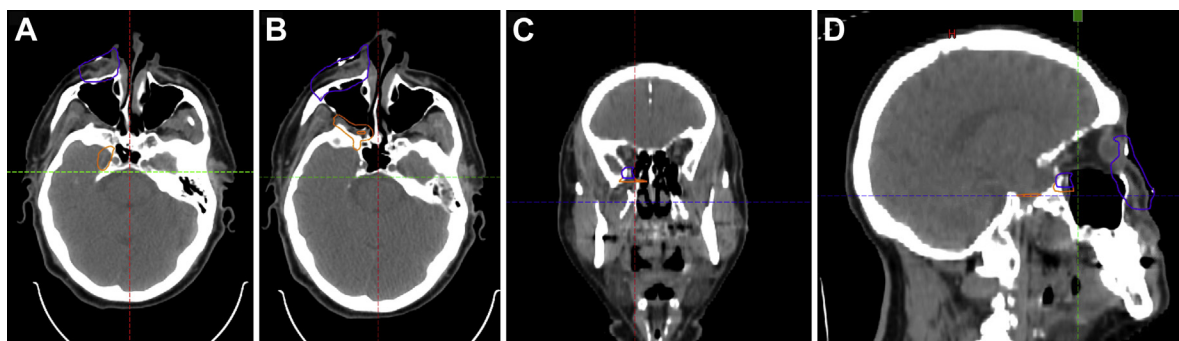


Figure 2 Clinical target volume (CTV) delineated by a radiation oncologist (RO) (blue) and with modifications by a neuro-radiologist (NR)/otolaryngologist (OL) (orange) on axial (A,B), coronal (C), and sagittal (D) computed tomography (CT) images.

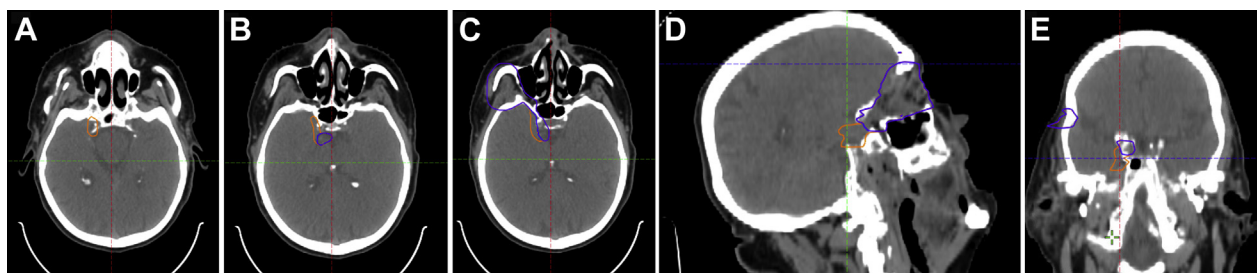


Figure 3 Clinical target volume (CTV) delineated by a radiation oncologist (RO) (blue) and with modification by a neuro-radiologist (NR)/otolaryngologist (OL) (orange) on axial (A-C), sagittal (D), and coronal (E) computed tomography (CT) images.

Discussion

In recent months, the use of commercially available, HIPAA-compliant VCP has exponentially increased to promote safe patient care during the COVID-19 pandemic.^{7,8} Our experience highlights the novel use of remote VCP to improve the quality of RT through multidisciplinary collaboration. Involvement of a radiologist and surgeon led to significant changes in the final RT target volumes for all cases. Remote VCP can overcome the logistical challenges that previously limited multidisciplinary involvement in RT treatment planning.

Although our institution uses Zoom, other VCPs with similar functionality are available, such as Microsoft Teams (Microsoft, Redmond, WA) and Cisco WebEx (Cisco, San Jose, CA). VCPs are low cost and require minimal additional infrastructure. VCPs can be accessed across multiple different interfaces, including computers, tablets, and smartphones. VCPs support multiple simultaneous users. VCPs are user-friendly and seamlessly integrate audio/video communication, screen-sharing, and screen control functionality. In our series, multidisciplinary contour review was supervised by the RO. Given that final treatment volumes are the medico-legal responsibility of the RO, we feel that this is the most appropriate approach. Our radiology and surgery colleagues had no prior experience with contouring in a TPS.

Therefore, brief structured training sessions may be helpful to improve contouring skills.¹⁰

The potential benefit of multidisciplinary involvement in RT treatment planning has been previously explored. An English group demonstrated that having a dedicated “in-house” radiologist in the radiation oncology department led to changes in target volumes in 25% of cases reviewed.⁶ Contour review during multidisciplinary tumor boards has also been suggested.¹¹ Two English centers have published short reports describing the feasibility of using VCPs to facilitate contour review between radiologists and ROs.^{12,13}

Interdisciplinary peer review is another method to improve the quality of RT target volumes.^{4,14} Memorial Sloan Kettering Cancer Center recently described their experience using a remote VCP to facilitate peer review of RT treatment planning for satellite cancer centers.¹¹ The University of Pennsylvania and Walter Reed Army Medical Center have collaborated to develop a VCP for shared RT planning for patients referred for proton therapy.¹⁵

The American Society for Radiation Oncology recently established the Peer-to-Peer Match program with the goal of fostering relationships to improve the quality of RT, especially in rural or underserved communities.⁵ This program is peer driven and ROs will use their own communication platforms to review cases. Telehealth

programs have been successfully implemented to improve the delivery of RT in Texas.¹⁶ The simplicity of commercially available VCPs makes them an ideal choice for this type of interdisciplinary peer review.

A recent survey demonstrated that nearly one-third of resident physicians received in-person contour review or contour feedback from attending physicians “rarely” or “sometimes.”¹⁷ Therefore, joint contour review via VCP could also serve as a convenient and safe platform to improve resident education.

Valid concerns have been raised about the security of VCPs.¹⁸ VCPs have since taken measures to improve security and privacy.¹⁹ Furthermore, users have gained more experience with VCPs in limiting unauthorized access. Institutions may have policies regarding the use of specific VCPs. The Department of Veterans Affairs has even developed their own VCP.²⁰ We are confident that most ROs will have access to a VCP that allows for this type of interdisciplinary review. Another challenge involves ensuring that interdisciplinary review remains HIPAA-complaint for physicians collaborating from different institutions. In clinical practice, external review of radiologic or pathology studies is commonly performed. Therefore, the treating RO could discuss the potential for peer review with the patient and obtain informed consent as needed.

Conclusions

Our experience highlights the feasibility of using a commercially available VCP for multidisciplinary target volume delineation in complex RT cases. Additional applications include interdisciplinary contour review for RT cases requiring special expertise and joint attending/resident physician contour review for resident education. This technology has demonstrated benefit during the COVID-19 pandemic, and we believe it will remain an integral component of our field moving forward.

References

- Eaton BR, Pugh SL, Bradley JD, et al. Institutional enrollment and survival among NSCLC patients receiving chemoradiation: NRG Oncology Radiation Therapy Oncology Group (RTOG) 0617. *J Natl Cancer Inst*. 2016;108:djw034.
- Kachnic LA, Winter K, Myerson RJ, et al. RTOG 0529: A phase 2 evaluation of dose-painted intensity modulated radiation therapy in combination with 5-fluorouracil and mitomycin-c for the reduction of acute morbidity in carcinoma of the anal canal. *Int J Radiat Oncol*. 2013;86:27-33.
- Chino JP, Lee WR, Madden R, et al. Teaching the anatomy of oncology: Evaluating the impact of a dedicated oncoanatomy course. *Int J Radiat Oncol*. 2011;79:853-859.
- Brunskill K, Nguyen TK, Boldt RG, et al. Does peer review of radiation plans affect clinical care? A systematic review of the literature. *Int J Radiat Oncol Biol Phys*. 2017;97:27-34.
- ASTRO. Peer-to-Peer Match Program. Available at: <https://www.astro.org/Patient-Care-and-Research/ROhub/Peer-to-Peer-Program>. Accessed June 8, 2020.
- Dimigen M, Vinod SK, Lim K. Incorporating a radiologist in a radiation oncology department: A new model of care? *Clin Oncol*. 2014;26:630-635.
- ASTRO. COVID-19's Impact on Radiation Oncology. Available at: <https://www.astro.org/ASTRO/media/ASTRO/News%20and%20Publications/PDFs/ASTROCOVID19Survey1-ExecSummary.pdf>. Accessed June 8, 2020.
- Price A, Henke LE, Maraghechi B, et al. Implementation of a novel remote physician SBRT coverage process during the coronavirus pandemic. *Adv Radiat Oncol*. 2020;5:690-696.
- Heyd R, Micke O, Surholt C, et al. Radiation therapy for Gorham-Stout syndrome: Results of a national patterns-of-care study and literature review. *Int J Radiat Oncol Biol Phys*. <https://doi.org/10.1016/j.ijrobp.2011.01.006>
- Jimenez RB, Yechieli R, Gunther JR, Golden DW, Fields EC. Introductory radiation oncology curriculum (IROC) for radiation oncology residents: Multi-institutional pilot implementation and evaluation. *Int J Radiat Oncol Biol Phys*. 2018;102:e391.
- Mueller BA, Obcemea C, Lee J, Sim S. Pilot study of a radiation oncology telemedicine platform. *J Radiat Oncol Inform*. 2017;2: 20-30.
- Morgan A, Isaac M, Scrutton S, Wedgewood J, Jankowska P, Hwang D. Using a commercial software package to support treatment planning peer review activities in small radiotherapy departments. *Br J Radiol*. 2015;88:20140864.
- Langmack K, Thomas A, Morgan D. The use of a commercial remote desktop program in the delineation of target volumes in radiotherapy. *Br J Radiol*. 2008;81:666-667.
- Hoopes DJ, Johnstone PA, Chapin PS, et al. Practice patterns for peer review in radiation oncology. *Pract Radiat Oncol*. 2015;5: 32-38.
- Belard A, Dolney D, Zelig T, McDonough J, O'Connell J. Improving proton therapy accessibility through seamless electronic integration of remote treatment planning sites. *Telemed J E-Health*. 2011;17:370-375.
- Lewis GD, Hatch SS, Wiederhold LR, Swanson TA. Long-term institutional experience with telemedicine services for radiation oncology: A potential model for long-term utilization. *Adv Radiat Oncol*. 2020;5:780-782.
- Sura K, Lischalk JW, Leckie J, Welsh JS, Mundt AJ, Fernandez E. Webinar-based contouring education for residents. *J Am Coll Radiol*. 2017;14:1074-1079.e3.
- Lorenz T. Zoombombing': When video conferences go wrong. *New York Times*; March 20, 2020. <https://www.nytimes.com/2020/03/20/style/zoombombing-zoom-trolling.html>.
- Singer N, Perlroth N, Krolik. Zoom rushes to improve privacy for consumers flooding its service. *New York Times*; April 8, 2020. <https://www.nytimes.com/2020/04/08/business/zoom-video-privacy-security-coronavirus.html>.
- VA Video Connect. Available at: <https://mobile.va.gov/app/va-video-connect#AppDescription>. Accessed September 5, 2020.